

Computer Aided Quantification of Synovitis in Rheumatoid Arthritis using Dynamic MRI & Impact of Movement Correction on Signal to Noise Ratio and Region of Interest Analysis

Mikael Boesen^{1,5}, Olga Kubassova^{2,5}, Marco Cimmino³, Mikkel Østergaard⁴, Bente Danneskiold-Samsøe⁵, Mette B. Axelsen⁴, and Henning Bliddal⁵

1) Department of Radiology, Frederiksberg Hospital, Copenhagen University Hospital, Denmark, 2) Image Analysis, Leeds, United Kingdom, 3) Department of Rheumatology, University of Genoa, Genoa, Italy, 4) Copenhagen University Hospital Hvidovre and Herlev, Copenhagen Denmark, 5) The Parker Institute, Frederiksberg Hospital, Copenhagen University Hospital Denmark

Background

Dynamic Contrast Enhanced MRI (DCE-MRI), based on repeated imaging of the same few MRI slices with a few seconds' interval after intravenous contrast injection, correlates closely to histological inflammatory activity and is a promising tool to assess the early response to treatment, potentially before volume changes and changes in OMERACT RAMRIS scores occur.

Analysis of DCE-MRI is usually done by manual selection of areas with most enhancement regions of interest (ROI), but variable ROI positioning and movements during imaging, introduce large variation in the results obtained from the dynamic curves using the ROI method.^{1,2}

Objective

To analyse DCE-MRI data from rheumatoid arthritis (RA) patients using a new algorithms for motion correction & to evaluate the impact of the motion correction techniques on SNR and diagnostic accuracy.

Data

DCE-MRI data were acquired in wrists of 50 RA patients and 5 controls by repeatedly obtaining 3 axial or coronal T1-weighted images every 10-15 seconds immediately after iv 0.1 mmol/kg Gd-DTPA, using a 0.2T Esaote C-scan or E-scan (22-30 repetitions).

Contact Information:

Mikael Boesen, MD, PhD
Department of Radiology
Frederiksberg Hospital
Copenhagen, Denmark
Tel: +45 3816 4629
Fax: +45 3816 4659
Email: mikael.boesen@gmail.com

Acknowledgment:

This study was supported by the Danish Rheumatism Association and the Oak Foundation.

References:

- McQueen FM et al. *Arthritis Rheum* 2004;50:674-5.
- Kubassova et al. Fast and Robust method for analysis of DCE-MRI Data, MICCAI'08 www.dynamika-ra.com

Data Analysis

The data was processed using Computer-Aided Detection software for rheumatologists Dynamika-RA (Image Analysis Ltd, www.imageanalysis.org.uk) that

1. Eliminated patient motion artefacts using an intensity-based algorithm which corrects for movements and breathing as well as allows adjusting changes in brightness and contrast.

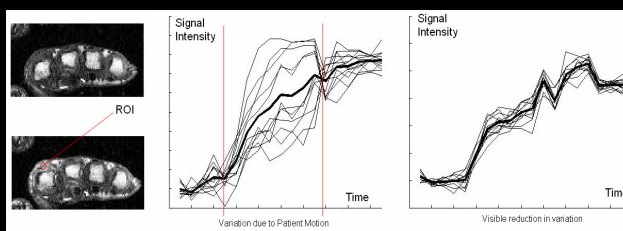


Figure 1. Pre- and post-contrast DCE-MR images (left). Middle: Signal Intensity vs. Time curves extracted from small ROI before (middle) and after (right) motion correction.

As a result of the patient motion correction variation in the shape of kinetic signal intensity vs. time curves was significantly reduced, which allowed observing the shape of the mean curve (in bold) more precisely (figure 1).

2. Analysed data using computer-guided ROI based method, where ROIs of 25mm² were positioned automatically in the area of most enhancement and statistics computed using Model Based Approach.²

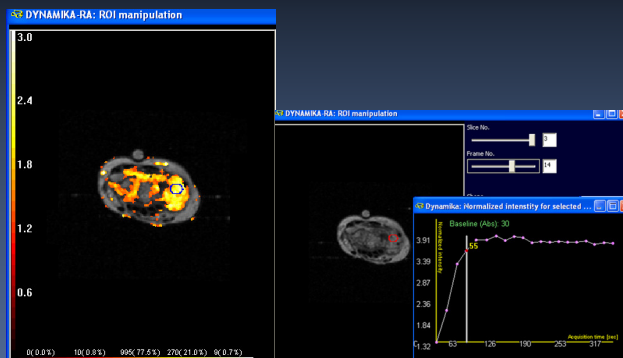


Figure 2. Computer guided ROI placement with Dynamika-RA, www.dynamika-ra.com

3. Maximum enhancement (ME) and Initial Rate of Enhancement (IRE) statistics were calculated automatically and stored in the reports.

Results

Motion artefacts in all 3 planes were reduced from 1.3mm±7mm to 1mm±1.5mm shift and 7±6degree to 1±0.4degree rotation.

SNR was increased by a factor 3 on average, image blurring was reduced and variations in the shape of dynamic curves extracted from the ROIs was reduced (figure 1).

This reduced variation in measurements of ME and IRE (statistical f-test was applied). In controls, the IRE was reduced from 0.21±0.1 to 0.12±0.02 [%/sec] and in ME from 0.35±0.23 to 0.1±0.01 [%]. In patients, IRE increased from 0.5±0.16 to 0.6±0.02 [%/sec] and ME from 0.53±0.3 to 0.7±0.02 [%].

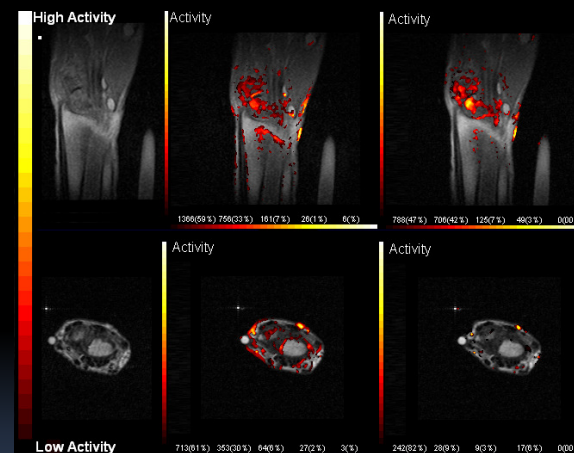


Figure 3. Top: Active RA patient. Bottom: Healthy control analysed using Dynamika-RA, www.dynamika-ra.com

Pre-contrast images (left), Parametric maps of Maximum Enhancement super-imposed on MR image showing inflammation before the motion correction (middle) and after (right). After the motion correction: visible reduction of skin enhancement and artefactual enhancement due to motion.

Conclusion

Elimination of motion artefacts significantly **reduced artefactual enhancement and increased SNR**. Reduced variation in ROI measurements significantly influenced the accuracy of quantitative analysis of inflammation.

This supports the use of DCE-MRI augmented by motion reduction algorithms for **more robust and valid analysis of synovitis in RA patients**.